

## Harmonic Focus Shears Versus Conventional Technique for Total Thyroidectomy

Running Head: Harmonic Scalpel in Thyroidectomy

Authors:

- <sup>1</sup>. Hakan Bulus, MD<sup>1</sup>
- <sup>2</sup>. Mutlu Sahin, MD,<sup>1</sup>
- <sup>3</sup>. Dogan Ozturk, MD<sup>1</sup>
- <sup>4</sup>. Alper Yavuz, MD<sup>1</sup>
- <sup>5</sup>. Veysel Baris Turhan, MD<sup>1</sup>
- <sup>6</sup>. Bulent Ozturk, MD<sup>1</sup>

<sup>1</sup> Kecioren Education and Research Hospital, Department of General Surgery, Ankara, Turkey

**Corresponding Author:** Hakan Bulus, M.D. **Address:** Kecioren Education and Research Hospital, Department of General Surgery, Pinarbasi mahallesi Sanatoryum caddesi Ardahan sok. No:1 Kecioren 06280, Ankara, TURKEY

**Phone:** +90 312 356 90 00

**Cell-phone:** +90 532 633 50 52

**Fax:** +90 312 356 90 02

### Abstract

#### Aim:

In thyroid surgery, hemostasis is generally maintained via suture ligation along with bipolar or monopolar electrocoagulation. However, harmonic scalpel (HS), which is an alternative technique for hemostasis, has also been preferred recently. In this study we evaluate the safety and feasibility of conventional thyroidectomy and HS thyroidectomy in open thyroidectomy.

#### Material and Method

80 patients who received total thyroidectomy for benign thyroid diseases were included in the study. Patients undergoing thyroidectomy were divided into 2 groups; group I, where the Harmonic FOCUS Shear was used, and group II, where electrocautery and clamp-and-tie technique were used for hemostasis.

#### Results:

There was no statistical difference detected between the groups in terms of average age, sex ratio and thyroid volumes. The duration of surgery was  $52.3 \pm 5.2$  minutes in Group I and  $71.3 \pm 2.8$  in the second ( $p=0.02$ ). The amount of drainage was  $42.1 \pm 23$  ml in group I and  $74.4 \pm 28$  ml in the second ( $p=0.03$ ). Level of postoperative pain was scaled with Visual Analog Scale (VAS) and it was  $3.3 \pm 1.3$  in Group I and  $4.7 \pm 1.7$  in the second ( $p=0.042$ ). Transitory

hypoparathyroidism was %25 (4) in Group I, it was %12.5 (2) in the second and this difference was considered statistically significant ( $p=0.04$ ).

**Conclusion:**

Harmonic Scalpel is a reliable and safe tool for thyroidectomy. Its utilization is associated with a shorter operative time, less drainage volume, and less postoperative pain.

**Keywords:**

Thyroidectomy, General surgery, Harmonic scalpel, Surgical devices, Complication

**Introduction:**

Total thyroidectomy is now being increasingly preferred for the management of multinodular goiter in order to avoid reoperations or potential complications that may emerge accordingly because of potential occult malignancies. Since the vascular plexus of the thyroid gland is highly sophisticated, it is both difficult to devascularize during the operation and it is also vital for hemostasis. In thyroid surgery, hemostasis is generally maintained via suture ligation along with bipolar or monopolar electrocoagulation. However, harmonic scalpel (HS), which is an alternative technique for hemostasis, has also been preferred recently (1,2).

HS is a device which simultaneously cuts and coagulates tissues by producing a vibration of 55.5 kHz frequency (Figure 1). When compared with conventional electro-surgical devices, this ultrasonic cutting and coagulating device has advantages such as causing a minimal lateral tissue injury (the HS causes lateral thermal injury 1-3 mm wide, approximately half that caused by bipolar systems), less fume, not making neuromuscular stimulation and keeping the electrical energy on the patient local. Ultrasonically activated shears are safe and fast devices in laparoscopic surgery(3,4). In addition, this new technology has been widely used in several fields of surgery, including otorhinolaryngologic, gastrointestinal, vascular, and obstetric and gynecological surgery(5,6,7).

In this study, we evaluated the safety and feasibility of the conventional thyroidectomy and HS thyroidectomy in open thyroidectomy.

**Material and Method**

80 patients who received total thyroidectomy for benign thyroid diseases between the dates May 2017 and June 2018 were included in the study. Excluded were patients with malignant disease, intrathoracic goiter, and previous neck operation or neck irradiation, as well as those who required central or lateral compartment lymphadenectomy, permanent medication for pain, and anticoagulation medication. All patients were operated on by the same surgeon. Patients undergoing thyroidectomy were divided into 2 groups; group I, where the Harmonic FOCUS Shear was used, and group II, where electrocautery and clamp-and-tie technique were used for hemostasis.

A total thyroidectomy for benign thyroid disease was performed with the patient under general anesthesia and with endotracheal intubation in all cases. A complete preoperative assessment

(serum thyrotropin levels, ultrasonography to evaluate nodule size and gland volume, and fine-needle aspiration cytology) was obtained in all patients.

Post operational thyroidectomy material volume was calculated and recorded in all cases. Figures of Visual Analog Scale (VAS) were recorded at the 12<sup>th</sup> and 24<sup>th</sup> hours after the surgery. Diclofenac Sodium was applied via intramuscular (IM) route as analgesic to patients with VAS figures higher than 40 millimeters. The total drainage in the first 24 hours after the surgery and the total cost of the patients to the social insurance institution after being discharged were recorded. The duration of the surgery was recorded from the moment at which the surgeon started incision to the moment when the skin was sutured. Besides, vocal cord injuries were also checked with laryngoscopy one week after the surgery, in terms of early recurrent laryngeal nerve injuries.

Following sterile covering, an incision of approximately 5cm's was applied in between the left and the right sternocleidomastoid muscle (SCM). Subplatysmal flaps were prepared, and the strap muscles were separated in the midline and laterally reflected. The inferior, middle and superior thyroid vessels were then divided either with the harmonic scalpel (Figure 2) or with conventional knot tying. During this step, every effort was made to identify and protect the recurrent laryngeal nerves. The same steps were repeated for the contralateral lobe. Finally, after irrigation of the wound, the strap muscles and the platysmal layer were approximated using continuous 4-0 polyglactin suture in an interrupted manner. A suction drain was applied to thyroidectomy gap and removed at the postoperative 24<sup>th</sup> hour.

All data were collected and analyzed using SPSS version 11.5 (SPSS, Chicago, IL, USA). Statistical analysis consisted of the chi squared-test and Student's *t*-test. *P*-values <0.05 were considered statistically significant.

### **Results:**

80 patients who received total thyroidectomy were included in the study. While the average age in the first group was  $47.5 \pm 12.5$ , it was  $48.01 \pm 11.2$  in the second group. Sex ratio in Group I was 31 females to 9 males and it was 29 females to 11 males in Group II. Thyroid volumes of the two groups were similar and measured as  $66 \pm 14.2$  and  $67.1 \pm 15.1$  respectively. No statistical difference was detected between the groups in terms of average age, sex ratio and thyroid volumes (Table 1).

The duration of surgery was  $52.3 \pm 5.2$  minutes in Group I and  $71.3 \pm 2.8$  minutes in the second ( $p=0,02$ ). When the amount of postoperative drainage and level of pain were examined; the amount of drainage was  $42.1 \pm 23$  ml in group I and  $74.4 \pm 28$  ml in the second ( $p=0,03$ ). Level of postoperative pain was scaled with Visual Analog Scale (VAS). It was  $3.3 \pm 1.3$  in Group I and  $4.7 \pm 1.7$  in the second ( $p=0,042$ ). The differences between the groups in terms of VAS, duration of surgery and total amount of drainage were considered statistically significant (Table 2).

No mortality was observed in either techniques of total thyroidectomy. While transitory hypoparathyroidism was %25 (4) in Group I, it was % 12.5 (2) in the second and this difference was considered statistically significant ( $p=0,04$ ). No wound site infection was observed in Group I, which was found to be %2.5(2) in Group II.

**Discussion:**

New safe and feasible surgical principles in thyroid surgery have been established over time, which used to have high rates of mortality and morbidity. No significant change in the technique of surgery was made following these standard principles. (8). Since the thyroid gland has a high hemorrhage, hemostasis is one of the most important steps of surgery. The conventional method of hemostasis is to bind the two ends of the vein. Because this is a time consuming method, surgeons have been tending towards alternative techniques of hemostasis. Monopolar–bipolar electrocautery, clips, staplers and lasers have been used accordingly but they have not received wide acceptance because of safety, feasibility and comfort problems (9).

Instruments which make use of different sources of energy were first used in laparoscopic surgery and have been accepted in many fields of surgery in time. Probably the most significant change in many years in thyroid surgery has been the use of these instruments. Harmonic scalpel is both a feasible device as it is capable of simultaneous cutting and coagulating with its ultrasonic vibration of 55.5 kHz and trustable with its minimal lateral thermal injury (10,11).

Hemorrhage is an important issue in thyroid surgery since it hinders exploration. Thus, hemostasis is a substantial step to clear the part. Ortega et al. stated in their work that hemorrhage which is observed especially in hyperthyroid cases is an important problem. They also mentioned the importance of hemostasis and feasibility of it when used in two steps (to solely coagulate the vein at first step and to coagulate and cut from distal at the second). Intra-operative hemorrhage was not taken into consideration in our study but in line with the impressions of Ortega et al, two-step usage of harmonic scalpel was effective even in problematical cases (12).

Miccoli and Meurisse examined the cases in terms of amount of postoperative drainage in their work and they observed less drainage in harmonic scalpel group than that of conventional group. We observed  $42.1 \pm 23$  ml of drainage in Group I and  $74.4 \pm 28$  ml in Group II. This difference between the groups is both in line with Miccoli and Meurisse’s work and is considered statistically significant (10, 13).

The procedure of binding and cutting the both ends of the vein in conventional thyroid surgery results in a longer duration of surgery. Instruments that make use of different types of energy have contributed to shortening the duration of surgery (10). Harmonic scalpel has also contributed to shortening the duration of surgery thanks to its advantage of simultaneous coagulation and cutting feature. Ecker et al examined the data of 12 randomized and controlled study (1153 cases) which they scanned through Cochrane and medline and proved that harmonic scalpel shortens the duration of surgery by 22.67 minutes (14). We observed in our study that the duration of surgery in group I (HS) was  $52.3 \pm 5.2$  minutes and  $71.3 \pm 2.8$  minutes in Group II

(C). This difference of 19 minutes in average is both considered significant and also consistent with the medical literature and proves that harmonic scalpel shortens the duration of surgery.

Shemen proves in his study that with a smaller incision than that of conventional surgery and with less traction and manipulation, it is possible to operate on the upper pole. Miccoli, on the other hand, reports in his randomized prospective study that there is a lower level of pain in the harmonic scalpel group than that of the conventional group. He attributes the fact that there is a lower level of pain in the harmonic scalpel group to the easiness of reaching the upper pole, to lower neck hyperextension and skin traction and to the fact that there is a lower possibility of edema occurrence thanks to the lower heat level in harmonic scalpel (10). We evaluated the level of postoperative pain with Visual Analog Scale (VAS) and found a VAS value of  $3.3 \pm 1.3$  in Group I whilst it was  $4.7 \pm 1.7$  in Group II. In parallel with Miccoli's and Shemen's works, the fact that we observed a lower level of pain in the harmonic scalpel group could be attributed to smaller incision, less traction and manipulation (10, 15). Since every case in our study was in the same posture during surgeries, the effect of neck hyperextension on the postoperative pain was equal but the low level of edema could be another reason for the lower level of pain in harmonic scalpel group.

**Conclusion:**

HS method is one of the methods that tries to make the preferred total thyroidectomy operation easier and non-complicated in the light of developing technology due to the risk of encountering increasing number of thyroid malignancies every day. We also observed that the HS method contributed positively to the operation time, postoperative drainage amount and pain status for the patient. We concluded that the increased risk of transient hypoparathyroidism is not important, as well as positive contributions. For these reasons, we think that thyroidectomy with HS method is one of the most effective, reliable and ergonomic methods among the existing methods despite the new methods developing over time.

**References:**

1. Friguglietti CU, Lin CS, Kulcsar MA. Total thyroidectomy for benign thyroid disease. *Laryngoscope*. 2003;113:1820-1826.
2. Siperstein AE, Berber E, Morkoyun E. The use of the harmonic scalpel vs conventional knot tying for vessel ligation in thyroid surgery. *Arch Surg*. 2002;137:137-142.
3. Voutilainen PE, Haglund CH. Ultrasonically activated shears in thyroidectomies: a randomized trial. *Ann Surg* 2000;231:322–8.
4. Laycock WS, Trus TL, Hunter JG. New technology for the division of short gastric vessels during laparoscopic Nissen fundoplication: a prospective randomized trial. *Surg Endosc*. 1996;10:71-73.

5. Takao S, Shinchi H, Maemura K, Aikou T. Ultrasonically activated scalpel is an effective tool for cutting the pancreas in biliary-pancreatic surgery: experimental and clinical studies. *J Hepatobiliary Pancreat Surg.* 2000;7:58-62.
6. Gertsch P, Pelloni A, Guerra A, Krpo A. Initial experience with the harmonic scalpel in liver surgery. *Hepatogastroenterology.* 2000;47:763-766.
7. Erian M, McLaren GR, Buck RJ, Wright G. Reducing costs of laparoscopic hysterectomy. *J Am Assoc Gynecol Laparosc.* 1999;6:471-475.
8. WF Becker. Presidential address: Pioneers in thyroid surgery. *Ann Surg.* 1977; 185: 493–504.
9. Kiriakopoulos A, Dimitrios T, Dimitrios L. Use of a diathermy system in thyroid surgery. *Arch Surg.* 2004 Sep;139: 997-1000.
10. Miccoli P, Berti P, Dionigi G, D'Agostino J, Orlandini C, Donatini G. Randomized controlled trial of harmonic scalpel use during thyroidectomy. *Arch Otolaryngol Head Neck Surg.* 2006 Oct;132(10):1069-73.
11. Roye GD, Monchik JM, Amaral JF. Endoscopic adrenalectomy using ultrasonic cutting and coagulating. *Surg Technol Int.* 2000; 9:129-138.
12. Ortega J, Sala C, Flor B, Lledo S. Efficacy and cost-effectiveness of the UltraCision harmonic scalpel in thyroid surgery: an analysis of 200 cases in a randomized trial. *J Laparoendosc Adv Surg Tech A.* 2004 Feb;14:9-12.
13. Meurisse M, Defechereux T, Maweja S, Degauque C, Vandelaer M, Hamoir E. [Evaluation of the Ultracision ultrasonic dissector in thyroid surgery. Prospective randomized study]. *Ann Chir.* 2000 Jun;125(5):468-72.
14. Ecker T, Carvalho AL, Choe JH, Walosek G, Preuss KJ. Hemostasis in thyroid surgery: harmonic scalpel versus other techniques--a meta-analysis. *Otolaryngol Head Neck Surg.* 2010;143:17-25.
15. Shemen L. Thyroidectomy using the harmonic scalpel: analysis of 105 consecutive cases. *Otolaryngol Head Neck Surg.* 2002;127:284-8.

**TABLES**

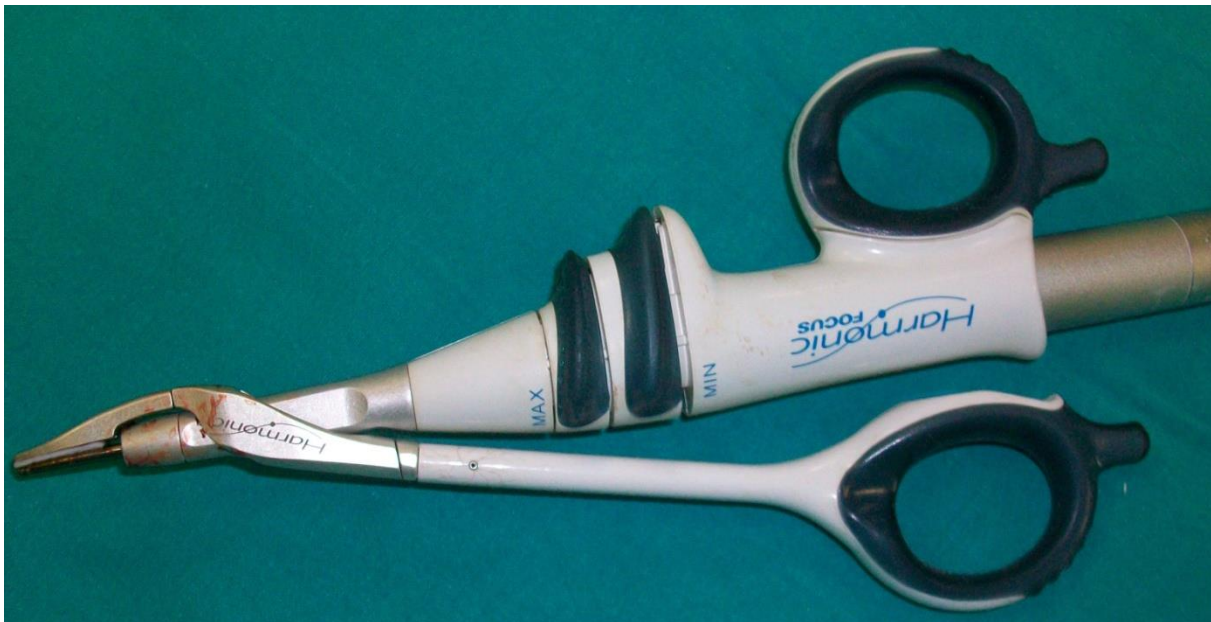	<b>GROUP I</b>	<b>GROUP II</b>	<b>p value</b>
<b>Gender F/M</b>	31/9	29/11	NS
<b>Age (Average)</b>	47.5 ± 12.5	48.01 ± 11.2	NS
<b>Thyroid volume (ml)</b>	66 ± 14.2	67.1 ± 15.1	NS
<b>Benign thyroid disorder</b>	40	40	NS

**Table 1.** Patient demographic and surgical characteristic (NS: Not significant)

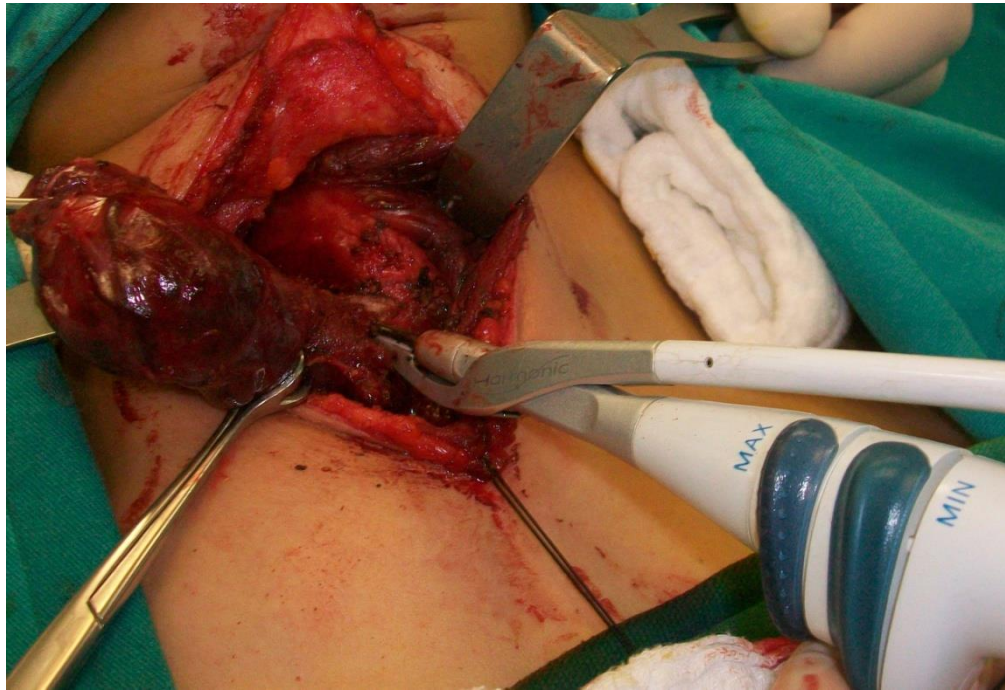
	<b>Group I N= 40</b>	<b>Group II N= 40</b>	<b>P VALUE</b>
Drain (ml)	42.1 ± 23	74.4 ± 28	<i>p</i> =0.03
VAS	3.3 ± 1.3	4.7 ± 1.7	<i>p</i> =0.042
Operation Time	52.3 ± 5.2	71.3 ± 2.8	<i>p</i> =0.02
Surgical site infection rate	0%	2.5(2) %	NS
Transient hypocalcemia	% 25(4)	% 12.5 (2)	<i>p</i> =0.04

**Table 2.** Outcome of comparison between groups

**FIGURES**



**Figure 1.** Harmonic scalpel focus shears



**Figure 2.** Ligation of the inferior thyroid vessels with the harmonic scalpel